

Misidentification of *Diphyllobothrium* Species Related to Global Fish Trade, Europe

Technical Appendix

Technical Appendix Table. Survey of cases of *Diphyllobothrium diphyllbothriosis* and *diplogonoporias* infections, Spain, 1983–2014*

Tapeworm species, subspecies	No. cases	Study	Remarks
<i>D. latum</i> †	1	Zerolo et al. 1983 (1)	No data or material available‡
<i>Diplogonoporus balanopterae</i>	1	Clavel et al. 1997 (2)	Indicated by proglottid morphology
<i>D. nihonkaiense</i> or <i>Diplogonoporus balanopterae</i> †	1	Gil-Setas et al. 2004 (3)	Indicated by egg morphology; no material available
<i>D. pacificum</i>	1	Colomina et al. 2002 (4)	Re-identified as ' <i>D. latum</i> ' by morphology
<i>D. pacificum</i>	1	Esteban et al. 2013 (5)	Re-identified as ' <i>D. latum</i> ' by DNA
<i>D. pacificum</i>	3	Pastor-Valle et al. 2014 (6)	DNA identification‡
<i>Diplogonoporus balanopterae</i>	1	Pastor-Valle et al. 2014 (6)	DNA identification‡

* *D. Diphyllbothrium.*

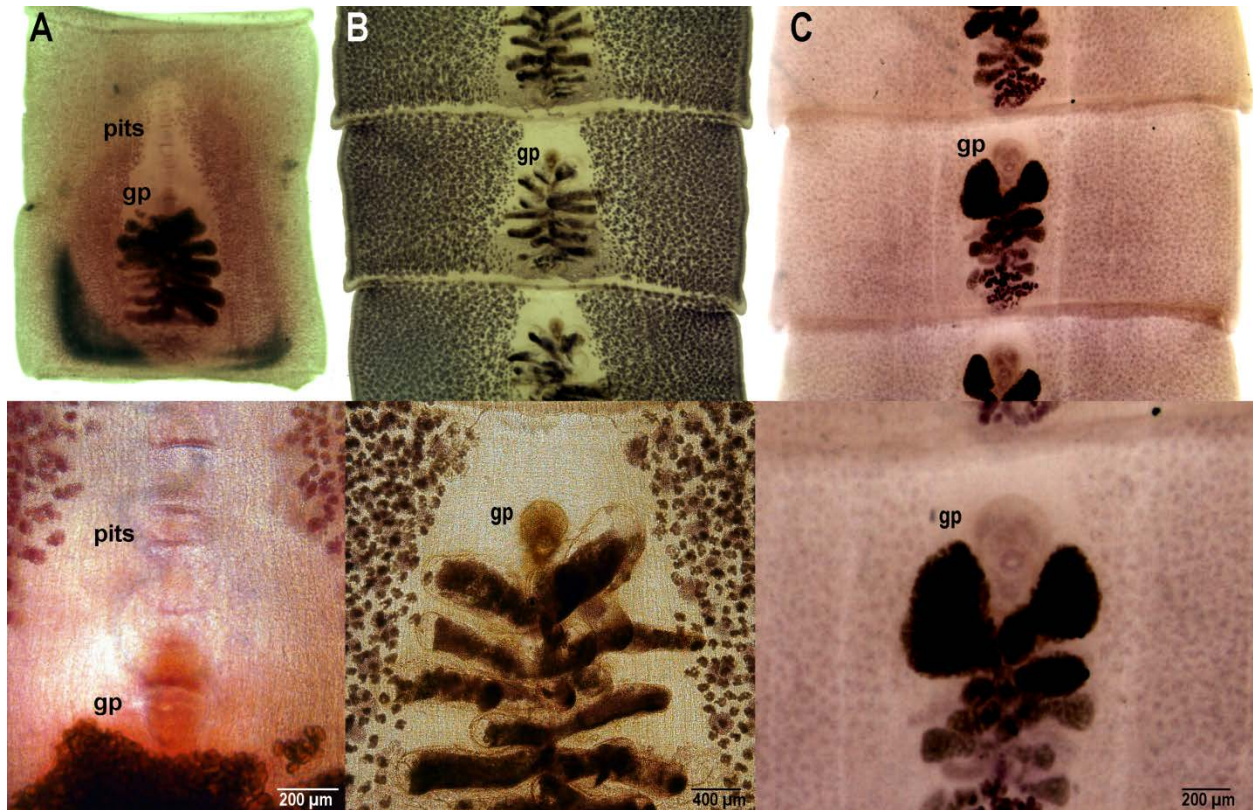
†Confirmation of identity not possible.

‡No morphological data provided.

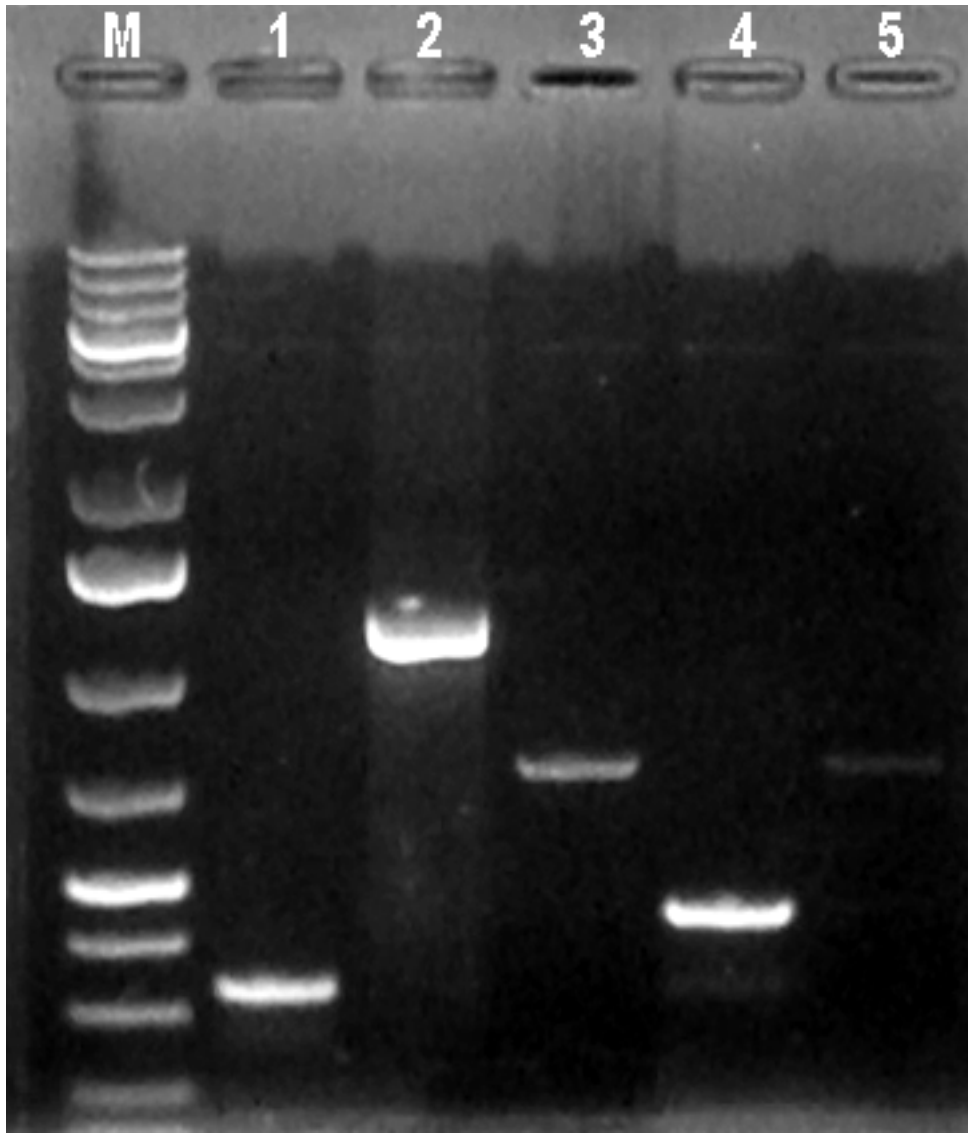
References

1. Zerolo FJ, Ibarra A, Escauriaza J, Ruiz P, Costan G. *Diphyllobothrium latum*: consideraciones a propósito de un caso en Córdoba. *Español.* 1983;2:76–8.
2. Clavel A, Bargues MD, Castillo FJ, Rubio MC, Mas-Coma S. Diplogonoporiasis presumably introduced into Spain: first confirmed case of human infection acquired outside the Far East. *Am J Trop Med Hyg.* 1997;57:317–20. [PubMed](#)
3. Gil-Setas A, Mazón A, Pascual P, Sagua H. Helminthiasis in a 71-year-old man, an infrequent condition in our setting [in Spanish]. *Enferm Infecc Microbiol Clin.* 2004;22:553–4. <http://dx.doi.org/10.1157/13067624>
4. Colomina J, Villar J, Esteban G. Asymptomatic infection by *Diphyllobothrium latum* in a Spanish 3-year-old child [in Spanish]. *Med Clin (Barc).* 2002;118:279. [PubMed](#) [http://dx.doi.org/10.1016/S0025-7753\(02\)72359-2](http://dx.doi.org/10.1016/S0025-7753(02)72359-2)
5. Esteban JG, Muñoz-Antoli C, Borrás M, Colomina J, Toledo R. Human infection by a “fish tapeworm”, *Diphyllobothrium latum*, in a non-endemic country. *Infection.* 2014;42:191–4. [PubMed](#) <http://dx.doi.org/10.1007/s15010-013-0491-2></jrn>

6. Pastor-Valle J, González LM, Martín-Clemente JP, Merino FJ, Gottstein B, Gárate T. Molecular diagnosis of diphyllobothriasis in Spain, most presumably acquired via imported fish, or sojourn abroad. *New Microbes and New Infections*. 2014;2:1–6. <http://dx.doi.org/10.1002/2052-2975.28>



Technical Appendix Figure 1. Photomicrographs of segments of diphyllobothriids from human. A) *Diphyllobothrium pacificum* reported by Esteban et al. (2013); B) *D. latum* (experimental human infection); C) *D. nihonkaiense* (case from Japan). gp, genital pore; pits, longitudinal pits anterior to the genital atrium typical of *D. pacificum*.



Technical Appendix Figure 2. Differential diagnosis of human-infecting *Diphyllobothrium* spp. by multiplex PCR after Wicht et al. 2010. Lane M, GeneRuler 1kb Plus Ladder (ThermoScientific); lane 1, *D. dendriticum* positive control (318 bp); lane 2, *D. nihonkaiense* positive control (1232 bp); lane 3, *D. pacificum* positive control (727 bp); lane 4, *D. latum* positive control (437 bp); lane 5; Esteban et al. (2013) amlicon.