

Pulmonary Infection Associated with *Mycobacterium canariasense* in Suspected Tuberculosis Patient, Iran

Appendix

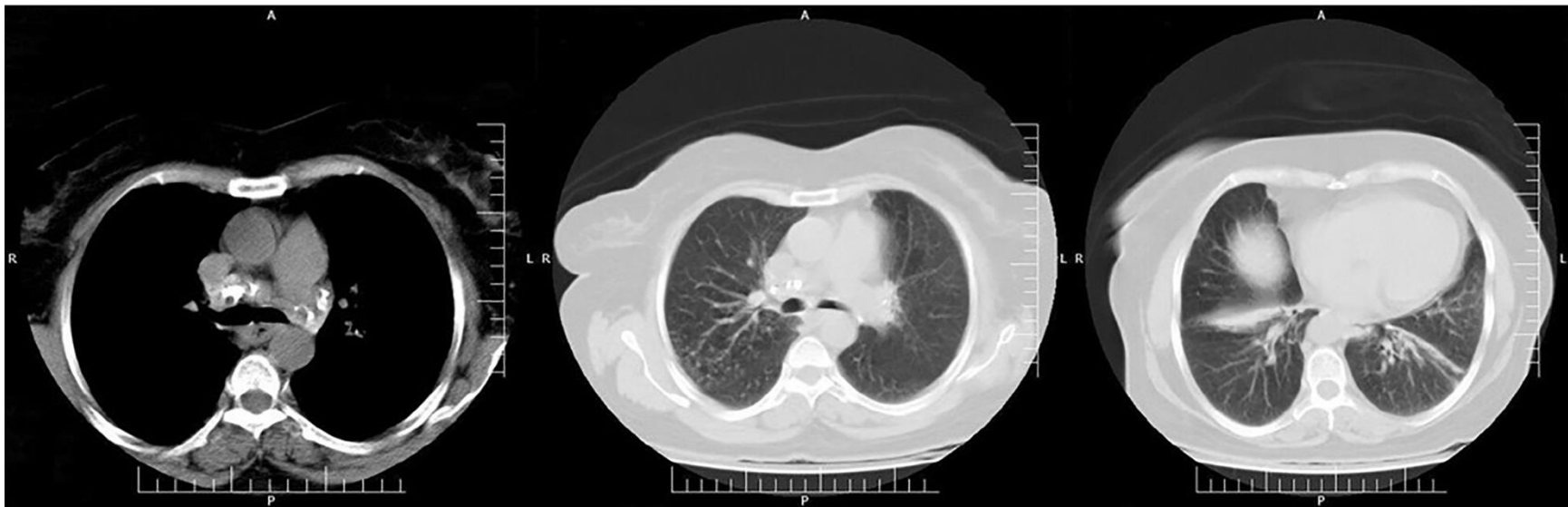


Figure: Chest CT scan image indicating calcified mediastinal lymph nodes, nodular opacities on both sides, a linear band in both lower lobes, partial wedge-shaped collapse in the right lower lobe, and fibrotic changes in the left lower lobe.