

the manuscript. Written consent for publication was obtained from the patient's wife.

Noémie Boillat, Blaise Genton, Valérie D'Acremont, Didier Raoult, and Gilbert Greub
 Author affiliations: University Hospital of Lausanne, Lausanne, Switzerland (N. Boillat, B. Genton, V. D'Acremont, G. Greub); and Mediterranean University, Marseilles, France (D. Raoult)

DOI: 10.3201/eid1412.070641

References

- Zhu Y, Fournier PE, Ereemeeva M, Raoult D. Proposal to create subspecies of *Rickettsia conorii* based on multi-locus sequence typing and an emended description of *Rickettsia conorii*. BMC Microbiol. 2005;5:11.
- Fournier PE, Dumler JS, Greub G, Zhang J, Wu Y, Raoult D. Gene sequence-based criteria for identification of new *Rickettsia* isolates and description of *Rickettsia heilongjiangensis* sp. nov. J Clin Microbiol. 2003;41:5456–65.
- Giammanco GM, Mansueto S, Ammatuna P, Vitale G. Israeli spotted fever *Rickettsia* in Sicilian *Rhipicephalus sanguineus* ticks. Emerg Infect Dis. 2003;9:892–3.
- Gross EM, Yagupsky P. Israeli spotted fever in children. A review of 54 cases. Acta Trop. 1987;44:91–6.
- Wolach B, Franco S, Bogger-Goren S, Drucker M, Goldwasser RA, Sadan N, et al. Clinical and laboratory findings of spotted fever in Israeli children. Pediatr Infect Dis. 1989;8:152–5.
- Bacellar F, Beati L, França A, Poças J, Regnery R, Filipe A. Israeli spotted fever rickettsia (*Rickettsia conorii* complex) associated with human disease in Portugal. Emerg Infect Dis. 1999;5:835–6.
- Giammanco GM, Vitale G, Mansueto S, Capra G, Caleca MP, Ammatuna P. Presence of *Rickettsia conorii* subsp. *israelensis*, the causative agent of Israeli spotted fever, in Sicily, Italy, ascertained in a retrospective study. J Clin Microbiol. 2005;43:6027–31.
- De Sousa R, Ismail N, Doria-Nobrega S, Costa P, Abreu T, França A, et al. The presence of eschars, but not greater severity, in Portuguese patients infected with Israeli spotted fever. Ann N Y Acad Sci. 2005;1063:197–202.
- Yagupsky P, Wolach B. Fatal Israeli spotted fever in children. Clin Infect Dis. 1993;17:850–3.
- Fournier PE, Raoult D. Suicide PCR on skin biopsy specimens for diagnosis of rickettsioses. J Clin Microbiol. 2004;42:3428–34.

Address for correspondence: Gilbert Greub, Institute of Microbiology and Service of Infectious Diseases, University Hospital Center and University of Lausanne, Bugnon, 46 Lausanne 1011, Switzerland; email: gilbert.greub@chuv.ch

***Streptococcus suis* Meningitis without History of Animal Contact, Italy**

To the Editor: *Streptococcus suis*, a major swine pathogen worldwide, is emerging as a zoonotic agent capable of causing a variety of serious infections in swine as well as in persons exposed to pigs or to pork products. These infections include meningitis, septicemia, pneumonia, endocarditis, arthritis, and septic shock (1,2). Despite recent outbreaks among persons in China, *S. suis* disease in humans is a rare, probably underdiagnosed infection that usually occurs as sporadic cases (1,2). Persons in close occupational or accidental contact with pigs or pork products and those who eat uncooked or undercooked pork may be at higher risk than others. However, most infected persons are likely healthy carriers, and *S. suis* is believed to induce overt disease (especially meningitis) in only some circumstances (2). We describe a case of *S. suis* meningitis in a 68-year-old man from Sardinia, Italy, who had no reported contact with swine, other animals, or any animal products; the patient also had cancer, which was discovered incidentally during the workup.

In November 2007, the patient was hospitalized with a 48-hour his-

tory of fever, headache, nausea, and general malaise. Physical examination showed impaired consciousness, nuchal rigidity, and a temperature of 39.5°C. Laboratory findings were 20,700 leukocytes/mm³ with 92% neutrophils, glucose 95 mg/dL, and C-reactive protein 375 mg/L. Cerebrospinal fluid (CSF) analysis demonstrated 240 leukocytes/μL with 80% polymorphonuclear cells, glucose 24 mg/dL, and protein 277 mg/dL. A computed tomography scan of the head showed no abnormal findings. Gram stain of CSF showed gram-positive cocci, mostly in pairs (Figure).

Empirical therapy consisted of intravenous ceftriaxone (2 g twice a day) and oral chloramphenicol (2 g once a day). On day 5, α -hemolytic streptococci were isolated from CSF on sheep blood agar and identified as *S. suis* by using APIStrep (bioMérieux, Marcy l'Etoile, France). Serotyping, performed by slide agglutination with specific antiserum (Statens Serum Institute, Copenhagen, Denmark), identified the isolate as serotype 2.

Antimicrobial drug-susceptibility testing, performed according to guidelines of the Clinical and Laboratory Standards Institute (www.clsi.org), indicated susceptibility to penicillin, ceftriaxone, chloramphenicol, levofloxacin, and vancomycin and resistance to erythromycin (MIC >128 mg/L) and tetracycline (MIC 16 mg/L). Erythromycin resistance was constitutive and was mediated by the *erm*(B) determinant; tetracycline resistance was mediated by *tet*(W). Multilocus sequence typing (<http://ssuis.mlst.net>) assigned the *S. suis* isolate to sequence type (ST) 1.

The patient, a retired welder, denied any recent occupational or even occasional contact with swine or other animals and had no history of eating raw or undercooked pork. The patient's condition improved; chloramphenicol was discontinued on day 10, but the 14-day course of ceftriaxone was completed. On day 6, the patient

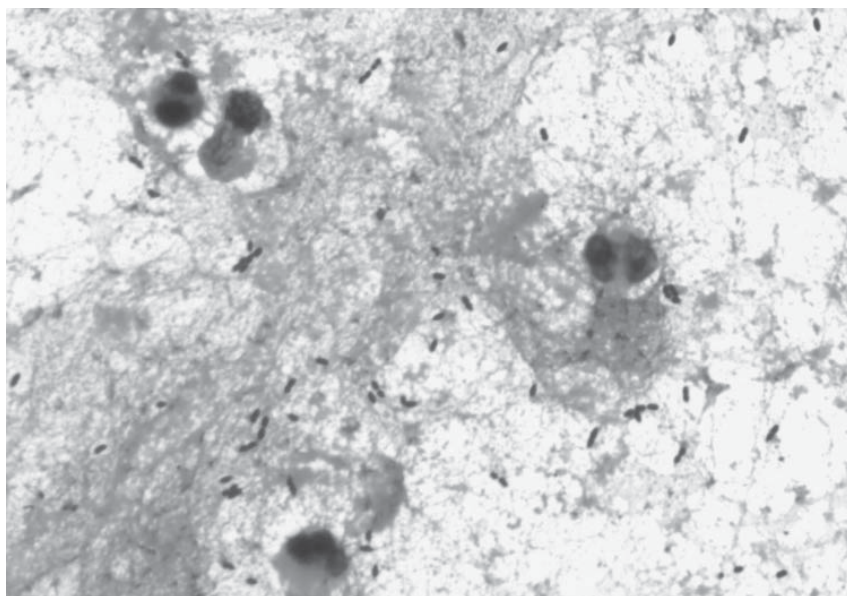


Figure. Gram-positive cocci, mostly in pairs, in cerebrospinal fluid from a 68-year-old man with *Streptococcus suis* meningitis. Magnification $\times 1,000$.

became afebrile but had dizziness and deafness; a formal audiology evaluation on day 9 showed severe bilateral sensorineural high-frequency hearing loss (-80 dB) that improved after a short course of dexamethasone. However, the patient was not discharged because of the lung mass found on initial chest radiograph. Computed tomography scan, bronchoscopy, and histopathologic findings led to diagnosis of the mass as an advanced-stage squamous cell carcinoma.

The meningitis had common and uncommon features. The common features were hearing loss, a typical outcome of *S. suis* meningitis independent of early antimicrobial drug administration (1,2); serotype 2, the most frequent and virulent serotype in swine and in humans (1,2); ST1, belonging to the ST1 complex, strongly associated with *S. suis* meningitis isolates (2,3); and *erm(B)*-mediated erythromycin resistance, widespread in this species (4). The uncommon features were tetracycline resistance mediated by *tet(W)*, increasingly detected in gram-positive and in gram-negative bacteria (5) but never previously reported in *S. suis* or in other

major streptococcal pathogens, where common determinants are *tet(M)* and *tet(O)*; and lack of evidence for recent contact with swine, other animals, or swine (pork) products.

Two previous cases of human *S. suis* meningitis in Italy (6,7) and other recent cases from Europe (8,9) were related to occupational exposure. However, the patient reported here also had cancer, and malignancy has been indicated as a predisposing factor for the development of severe *S. suis* disease in humans (2). These findings appear to be consistent with the recent suggestion of new epidemiologic patterns of infection caused by this organism (2). *S. suis* may become an opportunistic pathogen in persons who are under stress or who have immunodeficiency, and it has been increasingly isolated from mammalian species other than pigs, from birds, and from the environment. As also discussed in a recent survey (10), the possibility cannot be excluded that a patient with *S. suis* infection may be unaware or have no memory of previous exposure to animals. Alternatively, because asymptomatic carriage of *S. suis* has been documented in humans (2) and is

believed to contribute to its transmission (10), the possibility should also be considered that the infection may be a reactivation, possibly favored by malignancy, of latently colonizing *S. suis*.

Acknowledgment

We thank Chiara Magistrali for performing the slide agglutination test.

This work was supported in part by a grant to A.M. from Regione Sardegna, Ricerca Sanitaria Finalizzata 2007.

Aldo Manzin, Claudio Palmieri, Corrado Serra, Barbara Saddi, Maria Stella Princivalli, Giovanni Loi, Giuseppe Angioni, Franco Tiddia, Pietro E. Varaldo, and Bruna Facinelli

Author affiliations: University of Cagliari Medical School, Cagliari, Italy (A. Manzin, C. Serra); Polytechnic University of Marche Medical School, Ancona, Italy (C. Palmieri, M.S. Princivalli, P.E. Varaldo, B. Facinelli); SS. Trinità Hospital, Cagliari (B. Saddi, G. Angioni, F. Tiddia); and Azienda Ospedaliero-Universitaria, Cagliari (G. Loi)

DOI: 10.3201/eid1412.080679

References

1. Lun ZR, Wang QP, Chen XG, Li AX, Zhu XQ. *Streptococcus suis*: an emerging zoonotic pathogen. *Lancet Infect Dis*. 2007;7:201–9. DOI: 10.1016/S1473-3099(07)70001-4
2. Gottschalk M, Segura M, Xu J. *Streptococcus suis* infections in humans: the Chinese experience and the situation in North America. *Anim Health Res Rev*. 2007;8:29–45. DOI: 10.1017/S1466252307001247
3. Ye C, Zhu X, Jing H, Du H, Segura M, Zheng H, et al. *Streptococcus suis* sequence type 7 outbreak, Sichuan, China. *Emerg Infect Dis*. 2006;12:1203–8.
4. Martel A, Baele M, Devriese LA, Goossens H, Wisselink HJ, Decostere A, et al. Prevalence and mechanism of resistance against macrolides and lincosamides in *Streptococcus suis* isolates. *Vet Microbiol*. 2001;83:287–97. DOI: 10.1016/S0378-1135(01)00426-6
5. Roberts MC. Update on acquired tetracycline resistance genes. *FEMS Microbiol Lett*. 2005;245:195–203. DOI: 10.1016/j.femsle.2005.02.034

6. Perseghin P, Bezzi G, Troupioti P, Galina M. *Streptococcus suis* meningitis in an Italian blood donor. *Lancet*. 1995;346:1305–6. DOI: 10.1016/S0140-6736(95)91912-0
7. Camporese A, Tizianel G, Bruschetta G, Cruciatti B, Pomes A. Human meningitis caused by *Streptococcus suis*: the first case report from north-eastern Italy. *Infez Med*. 2007;15:111–4.
8. Hidalgo A, Roperio F, Palacios R, Garcia V, Santos J. Meningitis due to *Streptococcus suis* with no contact with pigs or porcine products. *J Infect*. 2007;55:478–82. DOI: 10.1016/j.jinf.2007.02.013
9. Taipa R, Lopes V, Magalhães M. *Streptococcus suis* meningitis: first case report from Portugal. *J Infect*. 2008;56:482–3. DOI: 10.1016/j.jinf.2008.03.002
10. Mai NT, Hoa NT, Nga TV, Linh LD, Chau TT, Sinh DX, et al. *Streptococcus suis* meningitis in adults in Vietnam. *Clin Infect Dis*. 2008;46:659–67. DOI: 10.1086/527385

Address for correspondence: Aldo Manzin, Department of Biomedical Sciences and Technologies, Section of Medical Microbiology, University of Cagliari Medical School, Presidio di Monserrato, Strada Statale 554 – Bivio Sestu, I-09042 Monserrato (CA), Italy; email: aldomanzin@medicina.unica.it

Equine Herpesvirus Type 9 in Giraffe with Encephalitis

To the Editor: Herpesviruses have been isolated from many mammals. Herpesvirus infection in natural hosts is often mild and is usually followed by a latent infection; however, cross-species herpesvirus infections cause severe and fatal diseases. Equine herpesvirus (EHV)–1 causes abortion, respiratory disease, and, occasionally, neurologic disorders in horses. EHV-1 infection is usually limited to equine species, although it has also been found in other species (1), in which it causes fatal encephalitis. Recent sequence analyses suggested that the equine

herpesviruses isolated in the United States from onagers (*Equus hemionus*), Grevy's zebras (*E. grevyi*), and Thomson's gazelles (*Gazella thomsoni*) are a subtype or variant of EHV-1 (2). With respect to epizootiology, the nonequine animals affected by EHV-1 or EHV-1–related virus were kept in enclosures adjacent to those of zebra species (Grevy's or Burchell's).

Another EHV-related virus was isolated from 2 Thomson's gazelles that had encephalitis and were kept with zebras (3). The virus was later found to be a new type of EHV, EHV-9, although it was serologically cross-reactive with EHV-1 (3). Recently, neutralizing antibodies against EHV-9 were found among Burchell's zebras in the Serengeti ecosystem (4).

A herpesvirus was recently isolated from a reticulated giraffe (*Giraffa camelopardalis reticulata*) with neurologic symptoms; the giraffe was from a zoo in the United States (5). Nonsuppurative encephalitis was found by histopathologic examination of the giraffe brain. Several Burchell's zebras that were apparently healthy and later determined to be seropositive for EHV-1 were housed in the same pen as the giraffe. The isolated virus was identified by PCR and a monoclonal antibody assay as EHV-1 (5). In the present study, we analyzed 4 gene sequences of the giraffe herpesvirus to show its relatedness to EHV-1 and EHV-9.

We amplified portions of 4 genes from giraffe herpesvirus DNA by PCR. The DNA polymerase catalytic subunit (open reading frame [ORF] 30) gene was amplified by using herpesvirus universal primers (6). The genes for glycoprotein B (gB) (ORF33), glycoprotein 2 (gp2) (ORF71), and glycoprotein D (gD) (ORF72) were amplified by using primers specific for EHV-9. The ORF33 primers were gB-F (5'-GGCACAATAGTCCTAGCATG TCTGTTGCTG-3') and gB-R (5'-AAATATCCTCAGGGCCGGAAC TGGAAAGTG-3'). The ORF71 prim-

ers were gp2-F (5'-CCCCGTTGATG AGTTTTGCGTAGAGGTCTA-3') and gp2-R (5'-GCCACCACTGGTTG TAAAGCCAAGAGATA-3'). The ORF72 primers were gD-F (5'-TTTACAACCACTGGTGGCGT GTGTGCAGAA-3') and gD-R (5'-TATCTCCAAACCGCGAAGCTT-TAAGGCCGT-3'). The amplified products were used as templates for direct sequencing (Dragon Genomics, Mie, Japan). The sequences were edited with Phred, Phrap, and Consed (www.phrap.org/phredphrapconsed.html), and the phylogenetic trees were constructed with PHYLIP (2,7). Accession numbers of the sequences (submitted to the DNA Data Bank of Japan) are given in the Figure.

We used PCR to amplify a part of the gB gene of the giraffe herpesvirus, and we used EHV-1 specific primers for sequencing. However, we could not obtain amplicons (data not shown). Therefore, the more conserved gene, ORF30, was sequenced. The sequence of the 1,066-bp segment of the giraffe herpesvirus ORF30 gene was 99.5% identical to EHV-9 and 94.6% identical to EHV-1, which indicates that the giraffe herpesvirus was most closely related to EHV-9. Therefore, EHV-9 ORF33–specific primers were used to amplify the corresponding region of the giraffe herpesvirus. The sequence of the giraffe herpesvirus ORF33 was 98.8% identical to EHV-9 and 95.9% identical to EHV-1. Also, the sequence of the other envelope glycoproteins (ORF71 and ORF72) of the giraffe herpesvirus were 99.8% and 99.6% identical to EHV-9 and 91.6% and 96.3% identical to EHV-1. A phylogenetic tree of maximum likelihood showed that EHV-9 and the giraffe virus formed a genetic group that was apparently distinguished from other genetic groups of EHV (Figure).

Herpesviruses have caused clinical disease in zoo animals, including a case of EHV-9 infection in Thomson's gazelles (3) and a recently described endotheliotropic betaherpesvirus in-