

CSF was negative for 16S bacterial RNA by PCR and culture-negative for *H. influenzae*, and the CSF pleocytosis had decreased substantially. These circumstances make it less likely that these signs were associated with the underlying *H. influenzae* disease and raise the possibility that superimposed HAdV-40 infection played a role. Because the patient had no diarrhea or respiratory symptoms, no evidence of immunodeficiency, no stool specimen available for testing, and no evidence of HAdV in throat swab specimen, the pathogenesis of HAdV-40 infection in this case is unknown. The origin of the maculopapular rash concurrent with neurologic symptoms in this patient is also unclear. Rash is not typical for *H. influenzae* infection and, although reported for some HAdV infections (7), has not been previously described for HAdV-40/41.

In conclusion, this case demonstrates the possibility of nongastroenteric, systemic infection involving CNS with enteric HAdV in immunocompetent hosts. Broad-specificity AdV PCR assay followed by amplicon sequencing enabled detection of this pathogen in an unexpected context and can be useful in defining the nongastroenteric disease effects associated with the enteric HAdVs.

Acknowledgments

We thank our collaborators from Thailand—Surapee Anantapreecha, Malinee Chittaganpitch, Sirima Pattamadilok, Ratigorn Guntapong, Watcharee Saisongkorh, and Sununta Henchaichon—for their contribution to the Thailand Encephalitis Study; Henry “Kip” Baggett for his helpful review of the manuscript; and the numerous collaborators at the National Institute of Health of Thailand and the Centers for Disease Control and Prevention who performed the testing of specimens for agents other than AdVs.

Nino Khetsuriani, Suxiang Tong, Xiaoyan Lu, Shannon Reed, Dean Erdman, Angela Campbell,¹ Krongkaew Supawat, Sahas Liamsuwan, Narayanan Jothikumar, and Sonja Olsen²

Author affiliations: Centers for Disease Control and Prevention, Atlanta, Georgia, USA (N. Khetsuriani, S. Tong, X. Lu, S. Reed, D. Erdman, A. Campbell, N. Jothikumar); National Institute of Health, Nonthaburi, Thailand (K. Supawat); Queen Sirikit National Institute of Child Health, Bangkok, Thailand (S. Liamsuwan); and International Emerging Infections Program, Nonthaburi (S. Olsen)

DOI: 10.3201/eid1502.081066

References

1. Uhnoo I, Svensson L, Wadell G. Enteric adenoviruses. *Baillieres Clin Gastroenterol.* 1990;4:627–42. DOI: 10.1016/0950-3528(90)90053-J
2. Slatter MA, Read S, Taylor CE, Crooks BN, Abinun M, Flood TJ, et al. Adenovirus type F subtype 41 causing disseminated disease following bone marrow transplantation for immunodeficiency. *J Clin Microbiol.* 2005;43:1462–4. DOI: 10.1128/JCM.43.3.1462-1464.2005
3. Echavarría M, Maldonado D, Elbert G, Videla C, Rappaport R, Carballal G. Use of PCR to demonstrate presence of adenovirus species B, C, or F as well as coinfection with two adenovirus species in children with flu-like symptoms. *J Clin Microbiol.* 2006;44:625–7. DOI: 10.1128/JCM.44.2.625-627.2006
4. Peck AJ, Supawat K, Liamsuwan S, Khetsuriani N, Bresee JS, Dowell SS, et al. Etiology of encephalitis in Thailand. In: Abstracts of the 43rd Annual Meeting of Infectious Disease Society of America; 2005 Oct 6–9; San Francisco; Abstract 141. San Francisco: the Society; 2005. p. 51.
5. Jothikumar N, Cromeans TL, Hill VR, Lu X, Sobsey MD, Erdman DD. Quantitative real-time PCR assays for detection of human adenoviruses and identification of serotypes 40 and 41. *Appl Environ Mi-*

crobiol. 2005;71:3131–6. DOI: 10.1128/AEM.71.6.3131-3136.2005

6. Lu X, Erdman DD. Molecular typing of human adenoviruses by PCR and sequencing of a partial region of the hexon gene. *Arch Virol.* 2006;151:1587–602. DOI: 10.1007/s00705-005-0722-7
7. Ramsay M, Reacher M, O’Flynn C, Buttery R, Hadden F, Cohen B, et al. Causes of morbilliform rash in a highly immunized English population. *Arch Dis Child.* 2002;87:202–6. DOI: 10.1136/adc.87.3.202

Address for correspondence: Nino Khetsuriani, Centers for Disease Control and Prevention, 1600 Clifton Rd NE, Mailstop E05, Atlanta, GA 30333, USA; email: nck7@cdc.gov

Mesotherapy-associated Outbreak Caused by *Mycobacterium immunogenum*

To the Editor: Mesotherapy, a procedure for medical and cosmetic treatment, involves use of microinjections of different biologically active substances into the dermis or subcutaneous adipose tissue. This controversial practice is used for spot contouring and anti-aging therapy. Concerns have been raised about mesotherapy complications, such as aseptic subcutaneous necrosis and cutaneous nontuberculous mycobacterial infections. Several rapidly growing mycobacterial species, primarily *Mycobacterium fortuitum*, *M. peregrinum*, *M. chelonae*, *M. abscessus*, *M. simiae*, and the newly described *M. massiliense*, *M. bolletii*, and *M. cosmeticum* (1–5), have been reported to cause infections and outbreaks originating from use of contaminated injectable solutions or skin antiseptics during mesotherapy and other invasive cosmetic procedures. We describe a mesotherapy-

¹Current affiliation: University of Washington, Seattle, Washington, USA.

²Current affiliation: Centers for Disease Control and Prevention, Atlanta, Georgia, USA.

associated outbreak involving an organism compatible with the novel *M. immunogenum* that Wilson et al. first described (6).

During September 2006–May 2007, 169 persons underwent mesotherapy at a private aesthetic clinic in the city of Buenos Aires, Argentina. For 28 (17%) skin lesions developed at the injection sites. Patients had been injected during the first 2 months of 2007 with phosphatidylcholine and ampelopsine after receiving a topical antiseptic containing lapyrium chloride from a commercial supplier. The clinic and all the products used in the procedure had been licensed by the national regulatory authority. As soon as the outbreak became evident, the antiseptic solution in use was discarded; no additional cases occurred. By the time the investigation was conducted, these solutions were no longer available for culture.

Nineteen patients were referred to our hospitals. Physical examination found 2–20 nodules 0.5–4 cm in diameter per patient. Lesions were localized on legs (18 patients), buttocks (16), abdomen (1), and forearms (1) and had appeared 7–37 days (median 31 days) after the injection. Occasionally, some nodules produced a serous or purulent discharge, but secretions were not submitted for bacteriologic analysis.

Nodule biopsy was performed for 10 patients, and specimens were sent for histologic and bacteriologic investigations. Histologic examination demonstrated abscesses, areas of fat necrosis, and peripheral fibrous changes. Specimens from 3 patients produced acid-fast bacilli growth in blood agar, mycobacteria growth indicator tube, and Lowenstein-Jensen culture media. When subcultured at 3 different temperatures for identification, all 3 cultures grew preferentially at room temperature rather than at 37°C and 42°C. The isolated mycobacteria were nonpigmented, rapidly growing, and fastidious. The results of

biochemical tests produced a hybrid pattern between *M. chelonae* and *M. abscessus*. Specifically, the isolates were unable to use citrate as the sole carbon source and to grow in the presence of 5% NaCl.

PCR-restriction analysis (PRA) of a 439-bp segment of the *hsp65* gene digested with *Bst*EII and *Hae*III was performed at the national reference laboratory for tuberculosis of the Instituto Malbran. Species was assigned according to the PRASITE website (<http://app.chuv.ch/prasite>). The profile of the 3 isolates fit the pattern of *M. immunogenum* type 2 as first described by Sampaio et al. (7); the isolates had 325- and 130-bp bands after *Bst*EII digestion and 200-, 70-, 58-, and 55-bp bands after *Hae*III digestion. This is our first detection of this particular PRA profile in Argentina since we started systematic *hsp65* PRA typing to identify mycobacteria in clinical isolates in 2005. Enterobacterial repetitive intergenic consensus PCR patterns of the 3 isolates were indistinguishable from each other

and differed from epidemiologically unrelated clinical isolates of the *M. abscessus*–*M. chelonae* group, confirming the clonality of the 3 strains (Figure) (7).

Susceptibility to antimicrobial agents was determined by using standard Clinical and Laboratory Standards Institute broth microdilution method (8). Clarithromycin, ciprofloxacin, cefoxitin, doxycycline, amikacin, tobramycin, and imipenem MIC values for the 3 isolates were <0.125, 1, 32, >32, 32, 16, and 64 µg/mL, respectively. The disk elution method produced similar patterns of activity for the first 4 antimicrobial agents and inconsistent results for the remaining 3. Patients received a combination of clarithromycin and either ciprofloxacin or levofloxacin for 6–8 months. All 19 cases resolved favorably, although multiple pigmented retractile scars persisted after treatment.

M. immunogenum was identified as the etiologic agent of a variety of hospital-acquired infections, including an outbreak of keratitis, and as

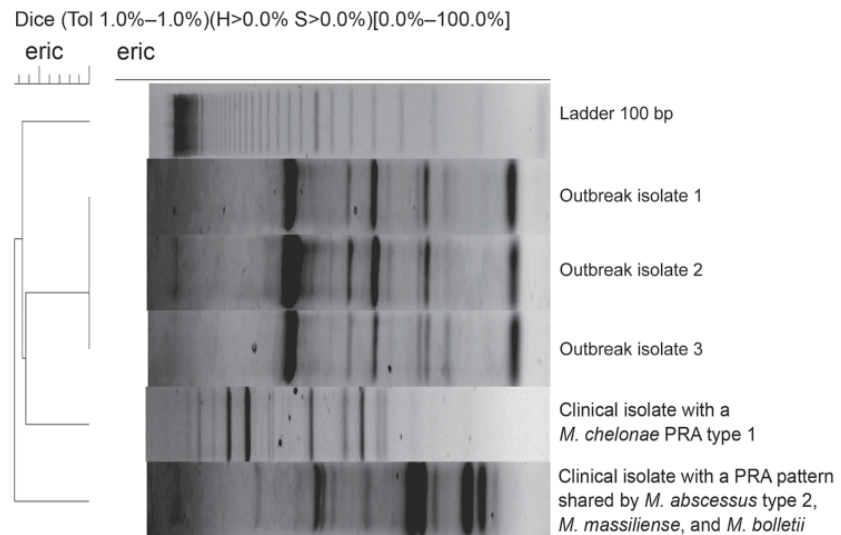


Figure. DNA enterobacterial repetitive intergenic consensus PCR (eric) analysis of rapidly growing mycobacteria isolated from 3 patients in a mesotherapy-associated outbreak, January–February, 2007, Buenos Aires city, Argentina, compared with profiles of epidemiologically unrelated clinical isolates of the *Mycobacterium abscessus*–*M. chelonae* group. The dendrogram was constructed with the aid of BioNumerics software version 4.6 (Applied Maths, Sint-Martens-Latem, Belgium), using Dice unweighted pair group method coefficients with 1% tolerance. PRA, PCR-restriction analysis of the *hsp65* gene.

the potential cause of hypersensitivity pneumonitis in industrial metal-grinding machinists (6,7,9). This microorganism appears to differ from other members of the *M. chelonae-abscessus* group by subtle mutations in *rpoB*, *hsp65*, the hypervariable region of 16S rRNA, and other housekeeping genes (5–7,9,10). The value of minor polymorphisms might be arguable for defining new species and for clinically managing patients. However, because of its rarity among clinical isolates in our country, the PRA type ascribed to *M. immunogenum* proved to be a useful epidemiologic marker to investigate this outbreak.

**Marcelo del Castillo,
Domingo J. Palmero,
Beatriz Lopez, Roxana Paul,
Viviana Ritacco, Pablo Bonvehi,
Liliana Clara, Marta Ambroggi,
Lucía Barrera, and Carlos Vay**

Author affiliations: Sanatorio Mater Dei, Buenos Aires, Argentina (M. del Castillo, C. Vay); Hospital F.J. Muñiz, Buenos Aires (D. Palmero, M. Ambroggi); Instituto Nacional de Enfermedades Infecciosas ANLIS C. G. Malbrán, Buenos Aires (B. Lopez, R. Paul, V. Ritacco, L. Barrera); Consejo Nacional de Investigaciones Científicas y Técnicas, Buenos Aires (V. Ritacco); Centro de Educación Médica e Investigaciones Clínicas, Buenos Aires (P. Bonvehi); Hospital Italiano,

Buenos Aires (L. Clara); and Universidad de Buenos Aires, Buenos Aires (C. Vay)

DOI: 10.3201/eid1502.081125

References

- Centers for Disease Control and Prevention. Outbreak of mesotherapy-associated skin reactions—District of Columbia area, January–February 2005. *MMWR Morb Mortal Wkly Rep.* 2005;54:1127–30.
- Cooksey RC, de Waard JH, Yakrus MA, Rivera I, Chopite M, Toney SR, et al. *Mycobacterium cosmeticum* sp. nov., a novel rapidly growing species isolated from a cosmetic infection and from a nail salon. *Int J Syst Evol Microbiol.* 2004;54:2385–91. DOI: 10.1099/ijs.0.63238-0
- Rivera-Olivero IA, Guevara A, Escalona A, Oliver M, Pérez-Alfonzo R, Piquero J, et al. Soft-tissue infections due to nontuberculous mycobacteria following mesotherapy. What is the price of beauty [in Spanish]. *Enferm Infecc Microbiol Clin.* 2006;24:302–6. DOI: 10.1157/13089664
- Munayco CV, Grijalva CG, Culqui DR, Bolarte JL, Suárez Ognio LA, Quispe N, et al. Outbreak of persistent cutaneous abscesses due to *Mycobacterium chelonae* after mesotherapy sessions, Lima, Peru. *Rev Saude Publica.* 2008;42:146–9. DOI: 10.1590/S0034-89102008000100020
- Viana-Niero C, Lima KV, Lopes ML, Rabello MC, Marsola LR, Brillhante VC, et al. Molecular characterization of *Mycobacterium massiliense* and *Mycobacterium bolletii* in isolates collected from outbreaks of infections after laparoscopic surgeries and cosmetic procedures. *J Clin Microbiol.* 2008;46:850–5. DOI: 10.1128/JCM.02052-07
- Wilson RW, Steingrube VA, Böttger EC, Springer B, Brown-Elliott BA, Vincent V, et al. *Mycobacterium immunogenum* sp. nov., a novel species related to *Mycobacterium abscessus* and associated with clinical disease, pseudo-outbreaks, and contaminated metalworking fluids: an international cooperative study on mycobacterial taxonomy. *Int J Syst Evol Microbiol.* 2001;51:1751–64.
- Sampaio JL, Junior DN, de Freitas D, Höfling-Lima AL, Miyashiro K, Alberto FL, et al. An outbreak of keratitis caused by *Mycobacterium immunogenum*. *J Clin Microbiol.* 2006;44:3201–7. DOI: 10.1128/JCM.00656-06
- Clinical and Laboratory Standards Institute. Susceptibility testing of mycobacteria, nocardiae, and other aerobic actinomycetes: approved standard [CLSI document M24-A]. Wayne (PA): The Institute; 2003.
- Wallace RJ Jr, Zhang Y, Wilson RW, Mann L, Rossmoore H. Presence of a single genotype of the newly described species *Mycobacterium immunogenum* in industrial metalworking fluids associated with hypersensitivity pneumonitis. *Appl Environ Microbiol.* 2002;68:5580–4.
- Adékambi T, Drancourt M. Dissection of phylogenetic relationships among 19 rapidly growing *Mycobacterium* species by 16S rRNA, *hsp65*, *sodA*, *recA* and *rpoB* gene sequencing. *Int J Syst Evol Microbiol.* 2004;54:2095–105. DOI: 10.1099/ijs.0.63094-0

Address for correspondence: Domingo J. Palmero, N. Videla 559, (1424) Buenos Aires, Argentina; email: djpalmero@intramed.net.ar

EMERGING INFECTIOUS DISEASES *online*

www.cdc.gov/eid

To receive tables of contents of new issues send an email to listserv@cdc.gov with subscribe eid-toc in the body of your message.