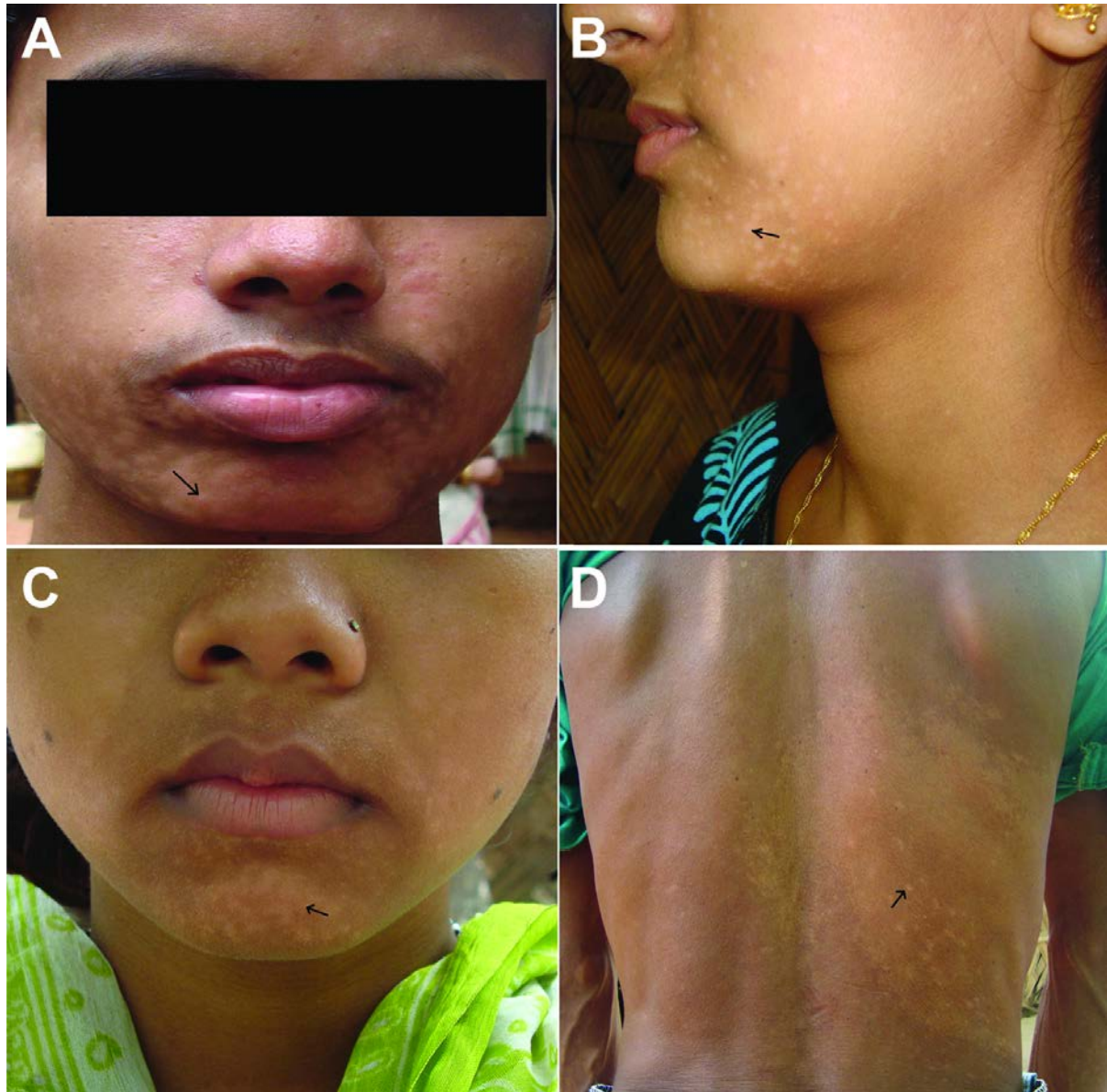


Kala-azar and Post-Kala-azar Dermal Leishmaniasis, Assam, India

Technical Appendix



Technical Appendix Figure. Skin lesions of patients with post-kala-azar dermal leishmaniasis, Assam, India. A) 16-year-old boy. B) 18-year-old woman. C) 16-year-old girl. (D) 45-year-old man.