

remain unknown. *S. delphini* has rarely been identified in horses, but, as we observed, it may be misidentified by conventional methods. Although colonization or contamination appeared most likely in the instances we describe, these findings suggest that this opportunistic pathogen can be found in horses and might be pathogenic in certain situations.

Our findings highlight the importance of using additional identification methods (e.g., MALDI-TOF, *Staphylococcus* species-specific PCR) for differentiation of SIG members (notably *S. delphini* and *S. pseudintermedius*) to effectively document the emergence of these species in horses. In addition, these findings indicate the need to ensure proper differentiation of *S. aureus* from SIG in equine isolates, despite the historical predominance of *S. aureus*, because of the differences in methods for determination of methicillin resistance. Future studies are needed to determine prevalence trends and disease roles for these species in equids.

**Jason W. Stull, Durda Slavić,
Joyce Rousseau,
and J. Scott Weese**

Author affiliation: University of Guelph,
Guelph, Ontario, Canada

DOI: <http://dx.doi.org/10.3201/eid2003.130139>

References

- Weese JS, van Duijkeren E. Methicillin-resistant *Staphylococcus aureus* and *Staphylococcus pseudintermedius* in veterinary medicine. *Vet Microbiol*. 2010;140:418–29. <http://dx.doi.org/10.1016/j.vetmic.2009.01.039>
- Ruscher C, Lubke-Becker A, Wleklinski CG, Soba A, Wieler LH, Walther B. Prevalence of methicillin-resistant *Staphylococcus pseudintermedius* isolated from clinical samples of companion animals and equidae. *Vet Microbiol*. 2009;136:197–201. <http://dx.doi.org/10.1016/j.vetmic.2008.10.023>
- Sasaki T, Kikuchi K, Tanaka Y, Takahashi N, Kamata S, Hiramatsu K. Reclassification of phenotypically identified *Staphylococcus intermedius* strains. *J Clin Microbiol*. 2007;45:2770–8. <http://dx.doi.org/10.1128/JCM.00360-07>
- Sasaki T, Tsubakishita S, Tanaka Y, Sakusabe A, Ohtsuka M, Hirota S, et al. Multiplex-PCR method for species identification of coagulase-positive staphylococci. *J Clin Microbiol*. 2010;48:765–9. <http://dx.doi.org/10.1128/JCM.01232-09>
- Goering RV, Morrison D, Al-Doori Z, Edwards GF, Gemmell CG. Usefulness of *mec*-associated direct repeat unit (*dru*) typing in the epidemiological analysis of highly clonal methicillin-resistant *Staphylococcus aureus* in Scotland. *Clin Microbiol Infect*. 2008;14:964–9. <http://dx.doi.org/10.1111/j.1469-0691.2008.02073.x>
- Perreten V, Kadlec K, Schwarz S, Grönlund Andersson U, Finn M, Greko C, et al. Clonal spread of methicillin-resistant *Staphylococcus pseudintermedius* in Europe and North America: an international multicentre study. *J Antimicrob Chemother*. 2010;65:1145–54. <http://dx.doi.org/10.1093/jac/dkq078>
- Geha DJ, Uhl JR, Gustafro CA, Persing DH. Multiplex PCR for identification of methicillin-resistant staphylococci in the clinical laboratory. *J Clin Microbiol*. 1994;32:1768–72.
- Weese JS, Rousseau J, Kadlec K, Guptil L, Goering RV, Schwarz S. Direct repeat unit (*dru*) typing of methicillin-resistant *Staphylococcus pseudintermedius* from North America and Europe. In: Abstracts of the International Society for Companion Animal Infectious Diseases Conference; San Francisco; 2012 Nov 14–17. Davis (CA): International Society for Companion Animal Infectious Diseases; 2012.
- Stegmann R, Burnens A, Maranta CA, Perreten V. Human infection associated with methicillin-resistant *Staphylococcus pseudintermedius* ST71. *J Antimicrob Chemother*. 2010;65:2047–8. <http://dx.doi.org/10.1093/jac/dkq241>
- Papich MG. Proposed changes to Clinical Laboratory Standards Institute interpretive criteria for methicillin-resistant *Staphylococcus pseudintermedius* isolated from dogs. *J Vet Diagn Invest*. 2010;22:160. <http://dx.doi.org/10.1177/104063871002200136>

Address for correspondence: Jason W. Stull,
The Ohio State University, 1920 Coffey Rd,
Columbus, OH 43210, USA; email: stull.82@osu.edu



Kala-azar and Post-Kala-azar Dermal Leishmaniasis, Assam, India

To the Editor: Kala-azar (visceral leishmaniasis) is a fatal disease caused by a protozoan parasite *Leishmania donovani* and transmitted by the female sandfly, *Phlebotomus argentipes*. In the state of Assam, India, kala-azar epidemics occurred during 1875–1950 and resulted in thousands of deaths in the districts of Kamrup, Garo Hills, Goalpara, and Nagaon (1,2). The disease gradually disappeared from Assam because of the extensive use of DDT in the national malaria elimination program, and results of later entomologic studies indicated that there were no *P. argentipes* sandflies in this region after DDT use (3). However, sporadic kala-azar cases appeared again in Assam in 2004 (4), and in 2008, we reported a kala-azar outbreak in Kamrup (5), where kala-azar epidemics had occurred during the 1870s (1).

At bimonthly intervals during 2012, we conducted house-to-house surveys in 4 villages in the district of Kamrup, for a total of 845 households and 4,376 persons. Residents are socioeconomically poor and depend on agriculture and nearby brick kiln industries for their livelihood; persons involved in these industries generally keep cattle, and areas of cow manure provide breeding sites for sandflies. Persons reported with fever for >2 weeks, anemia, weight loss, and palpable spleen or liver and who were negative for malaria were tested for kala-azar by using the rK39 diagnostic kit (InBios, Seattle, WA, USA). We obtained bone marrow biopsy samples from selected persons who exhibited the symptoms listed above. A total of 162 persons had positive kala-azar results according to rK39

testing during 2008–2012; of these, 44 (27%) were children. Microscopic examination of bone marrow biopsy samples from 5 persons showed *L. donovani* parasites. We treated kala-azar case-patients with sodium stibogluconate (SSG). During the survey we recorded 4 suspected cases of post-kala-azar dermal leishmaniasis (PKDL).

Case-patient 1, a 16-year-old boy (panel A in online Technical Appendix Figure, wwwnc.cdc.gov/EID/article/20/3/13-0260.pdf), was reported positive by rK39 for kala-azar in November 2008. After receiving 30 injections of SSG (20 mg/kg body weight), he became afebrile and his spleen decreased to a nonpalpable size. He gained weight, and hemoglobin improved to reference range. Three years after treatment, hypopigmented

macules developed on his face, abdomen, and hands.

Case-patient 2 was an 18-year-old woman (online Technical Appendix Figure, panel B). Kala-azar was diagnosed in 2011, and she received 30 injections of SSG. One year after completing treatment, hypopigmented macules developed on her face and hands.

Case-patient 3 was a 16-year-old girl (online Technical Appendix Figure, panel C). In 2008, after test results for kala-azar were positive, she received 30 SSG injections and clinically recovered. Macular hypopigmentation developed on her face and body 3.5 years after treatment.

Case-patient 4, a 45-year-old man (online Technical Appendix Figure, panel D), was found positive for kala-azar in 2008 and received 17 doses of SSG. He had discontinued treatment because signs and symptoms subsided considerably, and he became afebrile.

Case-patients 1–4 were clinically examined to exclude other dermal diseases caused by fungi, vitiligo, and leprosy. These persons were also tested, and found to be negative, for tuberculosis, hepatitis C virus, and hepatitis B surface antigen. We obtained punched skin biopsy samples from each case-patient; a pinch of biopsy samples were dab smeared on glass slides for examination for *L. donovani* parasites, and remaining samples were stored in RNAlater (QIAGEN, Hilden, Germany). We microscopically examined Giemsa-stained slides and found *L. donovani* parasite in 1 sample. Using QIAamp DNA Mini Kit (QIAGEN), we isolated parasite DNA from the samples and used it for the first round of PCR with primers 5'-AAATCGGCTCCGAGGCGGGAAAC-3' and 5'-GGTACTCTATCAGTAGCAC-3' as described by Salotra et al. (6). Primers encompassing a 385-bp fragment internal to the 592-bp of *L. donovani* minicircle kinetoplast DNA having sequence 5'-TCGGACGTGTGTG-

GATATGGC-3' and 5'-CCGATAATATAGTATCTCCCG-3' (7) were used for nested PCR. Three samples were positive (Figure). We treated PKDL case-patients with amphotericin B deoxycholate in accordance with World Health Organization guidelines (8), and these patients recovered clinically.

Resurgence of kala-azar in the Kamrup district after a 60-year absence poses new challenges to India's kala-azar elimination program. Of the 162 kala-azar cases detected, many were in children who had no history of visiting other kala-azar-endemic areas. These findings suggest local transmission of infection and are supported by the presence of the vector sandfly during the 2008 outbreak (5).

In India, PKDL develops in 5%–15% of treated kala-azar case-patients (9); in Sudan, conversion of kala-azar to PKDL is as high as 50% (10). PKDL cases act as reservoirs for kala-azar. Therefore, effective control depends on active surveillance for kala-azar and PKDL and treatment of kala-azar with antileishmanial drugs in accordance with Government of India guidelines (www.nvbdc.gov.in/Doc/Guidelines-Diagnosis-Treatment-KA.pdf, www.nvbdc.gov.in/Doc/PKDL-Guidelines-220512.pdf). Ecologic conditions of the areas where kala-azar outbreaks occurred are conducive to sandfly breeding; thus, regular spraying of DDT is needed. Preventive measures to control spread of kala-azar to other areas of Assam would be an effective step for the kala-azar control program.

**Abdul Mabood Khan,
Prafulla Dutta,
Siraj Ahmed Khan,
Swaroop Kumar Baruah,
Dina Raja, Kamal Khound,
and Jagadish Mahanta**

Author affiliations: Regional Medical Research Centre, Dibrugarh, India (A.M. Khan, P. Dutta, S.A. Khan, J. Mahanta); Gauhati Medical College and Hospital, Guwahati, India (S.K. Baruah, D. Raja);

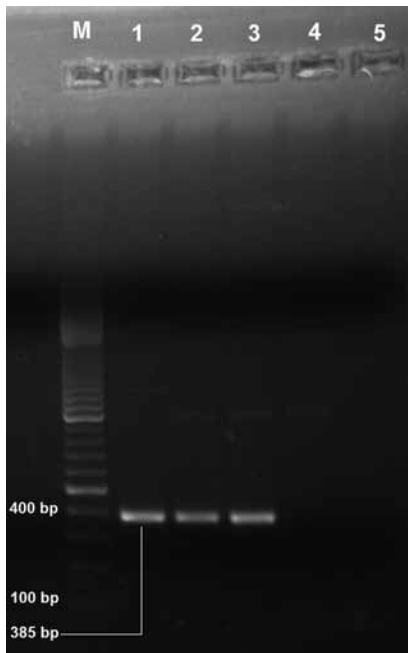


Figure. Electrophoretogram of *Leishmania donovani* kinetoplast DNA-specific PCR products (385 bp) isolated from patients with suspected post-kala-azar dermal leishmaniasis, Assam, India. Lane M, 100-bp DNA ladder; lanes 1–4, suspected post-kala-azar dermal leishmaniasis case-patients; lane 5, negative control. PCR products were visualized by staining with ethidium bromide after electrophoresis on a 1% agarose gel.

and National Vector Borne Disease Control Programme, Guwahati (K. Khound)

DOI: <http://dx.doi.org/10.3201/eid2003.130260>

References

1. Rogers L. The epidemic malarial fever of Assam, or kala-azar, successfully eradicated from tea garden lines. *Br Med J*. 1898; 2:891–2.
2. Price JD, Rogers L. The uniform success of segregation measures in eradicating Kala-azar from Assam tea gardens: it is bearing on the probable mode of infection. *BMJ*. 1914;1:285–9. <http://dx.doi.org/10.1136/bmj.1.2771.285>
3. Kaul SM, Sharma RS, Borgohain BK, Das NS, Verghese T. Absence of *Phlebotomus argentipes* Ann & Brun. (Diptera: Psychodidae) the vector of Indian kala-azar from Kamrup district, Assam. *J Commun Dis*. 1994;26:68–74.
4. Mathur P, Samantaray JC, Mangraj S. Smoldering focus of kala-azar in Assam. *Indian J Med Res*. 2004;120:56.
5. Khan AM, Pandey K, Kumar V, Dutta P, Das P, Mahanta J. Sample survey for indigenous cases of kala-azar in Assam by rk39 dipstick test. *Indian J Med Res*. 2009;129:327–8.
6. Salotra P, Sreenivas G, Pogue GP, Lee N, Nakhshi HL, Ramesh V, et al. Development of a species-specific PCR assay for detection of *Leishmania donovani* in clinical samples from patients with kala-azar and post-kala-azar dermal leishmaniasis. *J Clin Microbiol*. 2001;39:849–54. <http://dx.doi.org/10.1128/JCM.39.3.849-854.2001>
7. Sreenivas G, Ansari NA, Kataria J, Salotra P. Nested PCR assay for detection of *Leishmania donovani* in slit aspirates from post-kala-azar dermal leishmaniasis lesions. *J Clin Microbiol*. 2004;42:1777–8. <http://dx.doi.org/10.1128/JCM.42.4.1777-1778.2004>
8. World Health Organization. Control of leishmaniasis. Technical Report Series 949. Geneva: The Organization; 2010. p. 59–60.
9. Salotra P, Singh R. Challenges in the diagnosis of post kala-azar dermal leishmaniasis. *Indian J Med Res*. 2006;123:295–310.
10. Zijlstra EE, el-Hassan AM. Leishmaniasis in Sudan. Post kala-azar dermal leishmaniasis. *Trans R Soc Trop Med Hyg*. 2001;95(Suppl 1):S59–76. [http://dx.doi.org/10.1016/S0035-9203\(01\)90219-6](http://dx.doi.org/10.1016/S0035-9203(01)90219-6)

Address for correspondence: Abdul Mabood Khan, Regional Medical Research Centre, Division of Entomology and Filariasis, Northeastern Region (ICMR) Post Box No. 105, Dibrugarh, Assam 786001, India; email: abdulmaboodkhan@gmail.com

Septic Arthritis Caused by *Streptococcus suis* Serotype 5 in Pig Farmer

To the Editor: *Streptococcus suis* primarily infects pigs, but >700 human infections have been reported (1). Cases in human occur mainly in persons who have contact with pigs; these infections are most frequently reported in Southeast Asia (1). In humans, *S. suis* most often causes meningitis, but endocarditis, pneumonia, toxic shock-like syndrome, and septic arthritis have also been reported (1–3).

S. suis is classified into serotypes on the basis of the polysaccharide capsule. Among pigs, many serotypes cause severe infections, but nearly all human cases have been attributed to serotype 2 (1,3). Other serotypes have been isolated from humans only in a few cases: meningitis caused by serotype 4 (2); fatal bacteremia caused by serotype 16 (4); sepsis caused by serotype 24 (5); bacteremia, meningitis, and endocarditis caused by serotype 14 (6–8); and spontaneous bacterial peritonitis caused by serotype 5 (5). Here, we report a case of septic arthritis caused by *S. suis* serotype 5.

The patient was a 65-year-old pig farmer who had cut his hand at work; he had not noted cases of severe illness among his pigs. He had a history of benign hyperplasia of the prostate gland, and 1 year before the current illness, he received a diagnosis of right-sided coxarthrosis, for which radiographic imaging showed grade II changes, loss of cartilage, and subchondral sclerosis. One week after the patient cut his hand, his right hip became increasingly painful, and he sought treatment at a hospital. On examination, the trochanter major region was tender (not noted at previous examinations), and passive movement of the hip was painful. Blood test results showed a slight elevation of C-reactive

protein (CRP), to 31 mg/L (reference <5 mg/L). The symptoms were interpreted as trochanteritis, and treatment with nonsteroidal anti-inflammatory medication was instituted. The next day, the patient returned to the hospital with worsened pain and was admitted. He had a temperature of 37.7°C and a heart rate of 80 beats/min; blood test results showed a leukocyte count of 11.2×10^9 cells/L and CRP of 127 mg/L. Radiologic images of the hip were unremarkable, but ultrasonography-guided joint puncture showed pus and blood in the synovial fluid. Cultures were secured, and gram-positive cocci in short chains were noted in all blood culture bottles and in the synovial fluid culture. Treatment with intravenous cefotaxim was started.

Microbiological diagnosis of *S. suis* infection was made on the basis of colony morphology, a weak reaction with Lancefield anti-D antiserum, and a score of 2.31 according to matrix-assisted laser desorption/ionization–time of flight mass spectrometry (Biotyper version 3.0 software; Bruker Daltonics, Bremen, Germany). On the fourth day after admission, treatment was changed to benzylpenicillin (3 g 3×/d). The pain from the hip gradually declined, and CRP peaked at 337 mg/L on the fifth day after admission. On the seventh day after admission, treatment was changed to oral penicillin (2 g 3×/d) and was continued for 6 weeks.

At follow-up 6 months after the initial illness onset, the impairment in the patient's hip movement had worsened. Radiologic imaging showed necrosis of the femoral head, and the patient underwent total hip replacement surgery. During surgery, no signs of synovitis were noted, and 5 intraoperative cultures were negative. The procedure was completed without complications, and the patient's symptoms resolved.

The *S. suis* isolate from the patient was determined to be serotype 5 by Statens Serum Institut (SSI;