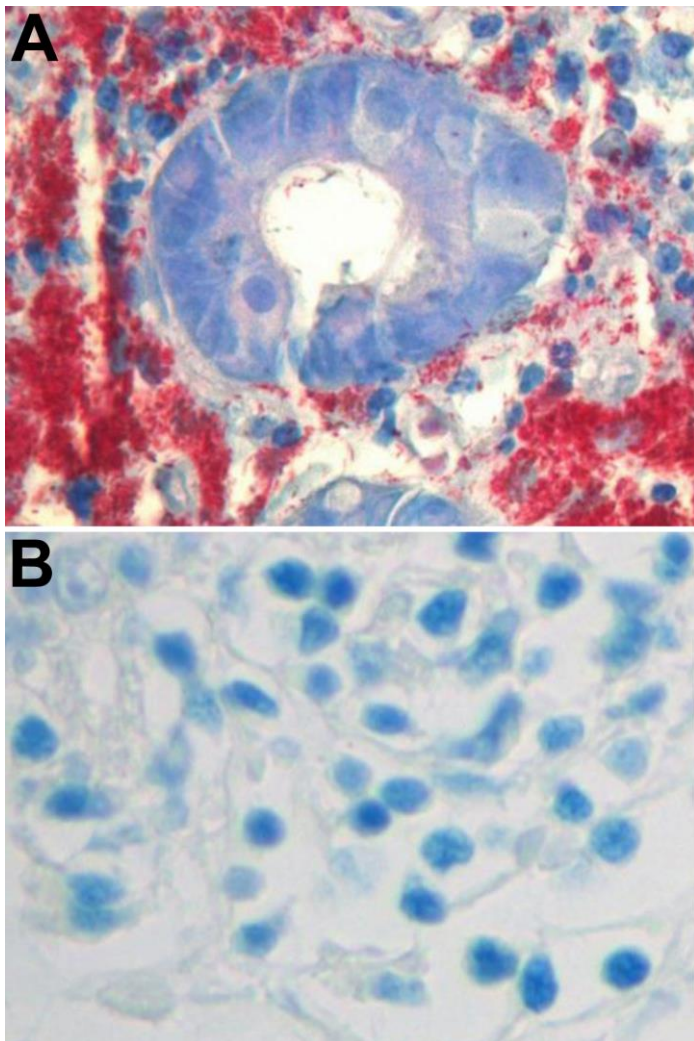


# Functional Immune Reconstitution by Therapy for HIV/Mycobacterial Co-infection

## Technical Appendix



Technical Appendix Figure. A) Abundant acid-fast bacilli on a stained histological specimen of a duodenal biopsy before the initiation of adjunctive interleukin-2 (IL-2) immunotherapy in an HIV-infected patient with disseminated *Mycobacterium tuberculosis* infection. B) Absence of acid-fast bacilli on a stained histological specimen of a duodenal biopsy after successful adjunctive IL-2 immunotherapy.