

acquired immunity or persistence of vaccine-derived immunity within the community, likely contributed to the restricted extent of secondary transmission. Further studies are needed to clarify risk factors for primary and secondary monkeypox transmission.

Positive serologic findings in healthcare workers during this investigation also highlight the limited infection prevention and control resources, such as isolation rooms, gowns, gloves, N95 respirators, and goggles, to protect healthcare workers responding to outbreaks in CAR. For communities located in remote forest areas in which zoonotic spillover and secondary transmission are thought to occur regularly, health center capacity and resources need to be strengthened. Health centers urgently need training on case recognition for healthcare workers, access to diagnostic capacities, and appropriate infection prevention and control measures to reduce the possibility of secondary transmission in these areas (10).

Acknowledgments

The authors thank Romain Duda for his assistance with identification of the animal species in Aka language.

About the Author

Dr. Besombes is an infectious and tropical disease clinician who works as a researcher in the Emerging Diseases Epidemiology Unit at Institut Pasteur, Paris, France. Her primary research interests include tropical diseases, specifically zoonotic and vectorborne diseases, and hepatitis Delta virus infection.

References

- Durski KN, McCollum AM, Nakazawa Y, Petersen BW, Reynolds MG, Briand S, et al. Emergence of monkeypox—West and Central Africa, 1970–2017. *MMWR Morb Mortal Wkly Rep*. 2018;67:306–10. <http://dx.doi.org/10.15585/mmwr.mm6710a5>
- Sklenovská N, Van Ranst M. Emergence of monkeypox as the most important orthopoxvirus infection in humans. *Front Public Health*. 2018;6:241. <http://dx.doi.org/10.3389/fpubh.2018.00241>
- Berthet N, Nakouné E, Whist E, Selekon B, Burguière AM, Manuguerra JC, et al. Maculopapular lesions in the Central African Republic. *Lancet*. 2011;378:1354. [http://dx.doi.org/10.1016/S0140-6736\(11\)61142-2](http://dx.doi.org/10.1016/S0140-6736(11)61142-2)
- Kalthan E, Tenguere J, Ndjapou SG, Koyazengbe TA, Mbomba J, Marada RM, et al. Investigation of an outbreak of monkeypox in an area occupied by armed groups, Central African Republic. *Med Mal Infect*. 2018;48:263–8. <http://dx.doi.org/10.1016/j.medmal.2018.02.010>
- Nakoune E, Lampaert E, Ndjapou SG, Janssens C, Zuniga I, Van Herp M, et al. A nosocomial outbreak of human monkeypox in the Central African Republic. *Open Forum Infect Dis*. 2017;4:ofx168. <http://dx.doi.org/10.1093/ofid/ofx168>
- ProMED-mail. Monkeypox—Africa (12): Central African Republic. 2018 Jul 30 [cited 2018 Oct 24]. <https://www.promedmail.org/archive/no.20180730.5936829>
- ProMED-mail. Monkeypox—Africa (05): Central African Republic (Haute-Kotto). 2018 Apr 4 [cited 2019 Jan 7]. <https://www.promedmail.org/archive/no.20180403.5726159>
- Li Y, Zhao H, Wilkins K, Hughes C, Damon IK. Real-time PCR assays for the specific detection of monkeypox virus West African and Congo Basin strain DNA. *J Virol Methods*. 2010;169:223–7. <http://dx.doi.org/10.1016/j.jviromet.2010.07.012>
- Di Giulio DB, Eckburg PB. Human monkeypox: an emerging zoonosis. *Lancet Infect Dis*. 2004;4:15–25. [http://dx.doi.org/10.1016/S1473-3099\(03\)00856-9](http://dx.doi.org/10.1016/S1473-3099(03)00856-9)
- Munster VJ, Bausch DG, de Wit E, Fischer R, Kobinger G, Muñoz-Fontela C, et al. Outbreaks in a rapidly changing Central Africa—lessons from Ebola. *N Engl J Med*. 2018;379:1198–201. <http://dx.doi.org/10.1056/NEJMp1807691>

Address for correspondence: Emmanuel Nakouné, Arboviruses, Viral Haemorrhagic Viruses, Emerging Viruses and Zoonosis Unit, Institut Pasteur de Bangui, Bangui, Central African Republic; email: emmanuel.nakoune@pasteur-bangui.org

Intact *Mycobacterium leprae* Isolated from Placenta of a Pregnant Woman, China

Zhiming Chen,¹ Yanfei Kuang,¹ Haiqin Jiang, Wenyue Zhang, Ying Shi, Santosh Chokkakula, Huan Chen, Junhua Li, Hongsheng Wang

Author affiliations: Chinese Academy of Medical Sciences Institute of Dermatology, Nanjing, China (Z. Chen, H. Jiang, W. Zhang, Y. Shi, S. Chokkakula, H. Wang); Hunan Provincial Center for Disease Control and Prevention, Changsha, China (Y. Kuang, H. Chen, J. Li); Jiangsu Key Laboratory of Molecular Biology for Skin Diseases and STIs, Nanjing (H. Wang); Nanjing Medical University Center for Global Health, Nanjing (H. Wang)

DOI: <https://doi.org/10.3201/eid2508.190114>

Whether *Mycobacterium leprae* transmits from placenta to fetus remains unknown. We describe the case of a pregnant woman with untreated histoid leproma. Although her newborn was healthy, laboratory examination revealed intact *M. leprae* present in the placenta, suggesting that the placental barrier might prevent vertical dissemination of *M. leprae*.

¹These authors contributed equally to and are co-first authors for this article.

Leprosy is an infectious disease caused by *Mycobacterium leprae* in susceptible persons. The disease affects the skin and peripheral nerves and, in later stages, can cause irreversible disability. Dissemination of *M. leprae* is thought to occur through nasal mucosa (1). However, in pregnant patients, whether *M. leprae* can transmit to the fetus remains unknown. We report the case of a pregnant

woman who had histoid leproma and refused therapy until after birth. The Ethics Committee of the Chinese Academy of Medical Sciences' Institute of Dermatology approved this study, and all persons provided informed consent before sample collection.

In December 2017, a pregnant woman sought care at the Chinese Academy of Medical Sciences' Institute of

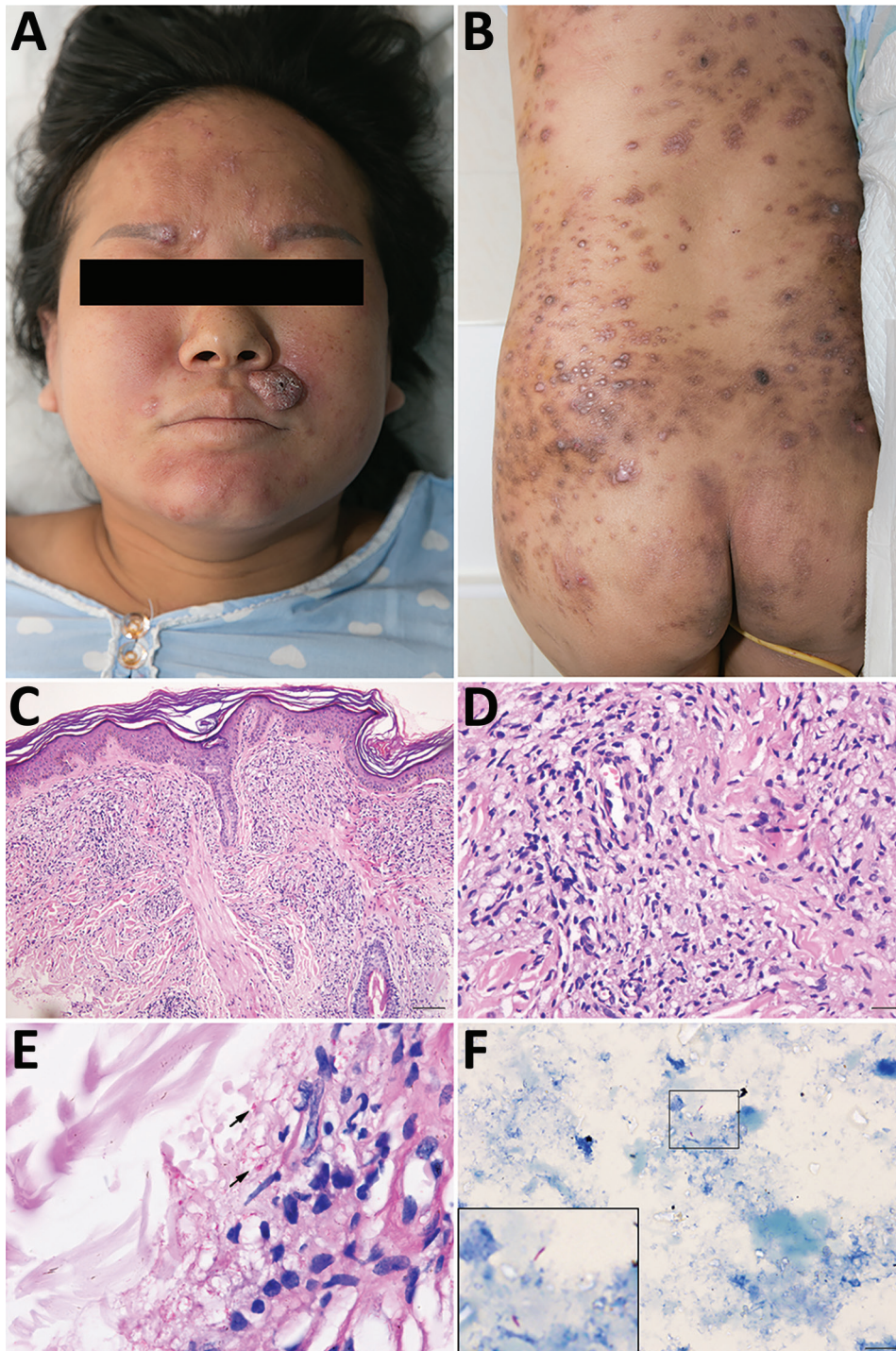


Figure. Clinical features of *Mycobacterium leprae* infection in pregnant woman and pathologic characteristics of a biopsy and placenta samples, China, December 2017. A, B) multiple brown papules and firm nodules on the woman's trunk and face and ichththyosis presentation on the anterior tibia. C, D) Testing of biopsy sample from the face demonstrates subepidermal clear zone, nodular proliferation of spindle-shaped histiocytes in the dermis. Hematoxylin and eosin stain; original magnification $\times 10$ (C) and $\times 40$ (D). E) Numerous acid-fast bacilli in dermis (arrows). Acid-fast stain; original magnification $\times 100$. F) Intact rod-shaped *M. leprae* from placenta homogenate; inset shows larger view. Acid-fast stain, original magnification $\times 100$.

Dermatology (Nanjing, China) with a 9-month history of asymptomatic multiple erythema and nodose lesions on her trunk. She had experienced dry skin and dysesthesia in both lower extremities for ≥ 10 years. In 2009, she had a sudden rash of erythema on her trunk and lower extremities, which was treated as eczema, without improvement. She began losing her eyebrows in 2015. Her pregnancy was discovered 3 months before admission. Since her illness onset, she had experienced no fevers or joint pain, and her family history was negative for leprosy.

Physical examination revealed multiple brown papules and firm nodules on her trunk and face (Figure, panels A, B). Superficial sensation was slightly impaired over the lower extremities. No peripheral nerve or superficial lymph node enlargement was observed. Her eyebrows were lost completely. A skin biopsy from her face revealed a subepidermal clear zone, numerous foamy histiocytes throughout the dermis, dense cellularity, and few perivascular lymphocytes. Prominent acid-fast bacilli were observed inside the dermis (Figure, panels C–E). PCR was performed to detect *M. leprae* DNA fragments of *RLEP* and *FolP1*. Samples from a facial lesion tested positive. Serologic examination of the patient's peripheral blood using ELISA was positive for antibodies of NDO-BSA (IgM), MMP-II (IgG), and LID-1 (IgG) (Appendix Table 1, <https://wwwnc.cdc.gov/EID/article/25/8/19-0114-App1.pdf>).

The patient refused treatment, citing concern about adverse effects on the fetus. Her condition was monitored with ultrasounds at serial intervals. At 37 weeks' gestation, her amniotic membranes ruptured. She was transferred to an isolated operating room and underwent a cesarean delivery. She delivered a healthy baby girl. At the patient's request, she was housed separately from her infant, and she decided not to breast-feed. After delivery, the patient was treated with dapson, rifampin, and clofazimine, in accordance with World Health Organization recommendations (2).

After delivery, we collected fresh samples from the patient, including breast milk, umbilical cord, umbilical cord blood, and placenta, as well as nasal mucosa swab and serum specimens from the patient, her newborn, and her elder daughter for bacterial and serologic analysis. Intact acid-fast bacilli were found in placenta homogenates from the patient (Figure, panel F; Appendix Figure). Serologic testing for NDO, MMP-II, and LID antibodies by ELISA were all positive in the patient, whereas only MMP-II and LID antibodies were found in the newborn (Appendix Table 1). We also conducted PCR testing of various samples; some results were positive for the mother and her elder daughter, but none were positive for the newborn (Appendix Table 2). One month later, serologic test results for the infant were almost negative for *M. leprae* antibodies (Appendix Table 3). The patient's lesions resolved, and her family members were shown to be healthy during follow-ups.

Leprosy can be exacerbated during pregnancy and, without treatment, can cause permanent damage to the skin, nerves, and eyes because of suppression of cell-mediated immunity in pregnancy. Downgrading reactions can occur, especially in the third trimester (3). Therefore, treating leprosy during pregnancy is critical. For multibacillary leprosy patients, World Health Organization treatment guidelines recommend multidrug therapy using rifampin, dapson, and clofazimine (2). These agents must never be used alone as monotherapy for leprosy nor be stopped during pregnancy (4).

Our patient refused treatment, citing concerns for adverse effects on the fetus; consequently, her condition dramatically worsened during the third trimester. Fortunately, no nerves or important organs were damaged. The patient's breast milk was negative for DNA, RNA, and antibodies of *M. leprae*. Serum samples from umbilical cord blood were positive for DNA and IgG of *M. leprae* but negative for RNA and IgM. Notably, a substantial number of *M. leprae* organisms were detected in the placenta (Figure, panel F; Appendix Figure).

Our findings support the assumption that the placental barrier can effectively stop vertical transmission of leprosy as well as the consensus that breast-feeding by women receiving multidrug therapy is safe for infants, given that no DNA or RNA of *M. leprae* were detected in breast milk (5,6). Although antileprosy drugs can be excreted into breast milk, no adverse effects have been reported except skin discoloration in the infant because of clofazimine (7). The patient's elder daughter's serum sample and nasal mucosa swab specimen were positive for *M. leprae* DNA and RNA by PCR, confirming that she was an *M. leprae* carrier. Households experiencing such a situation need to be screened with regular follow-ups (8).

Acknowledgments

We thank Lemuel Tsang for his invaluable suggestions during manuscript preparation.

This study was supported by the CAMS Innovation Fund for Medical Sciences (grant nos. 2016-I2M-1-005 and 2017-I2M-B&R-14) and Jiangsu Provincial Key Research and Development (grant no. BE2018619).

About the Author

Dr. Zhiming Chen works at the Chinese Academy of Medical Sciences' Institute of Dermatology and at Peking Union Medical College. His major research interests are cutaneous mycobacterial infection and genodermatosis.

References

1. Job CK, Jayakumar J, Kearney M, Gillis TP. Transmission of leprosy: a study of skin and nasal secretions of household contacts of leprosy patients using PCR. *Am J Trop Med Hyg.* 2008;78:518–21. <http://dx.doi.org/10.4269/ajtmh.2008.78.518>

2. World Health Organization. Chemotherapy of leprosy. World Health Organ Tech Rep Ser. 1994;847:1–24.
3. Duncan ME, Pearson JM, Ridley DS, Melsom R, Bjune G. Pregnancy and leprosy: the consequences of alterations of cell-mediated and humoral immunity during pregnancy and lactation. *Int J Lepr Other Mycobact Dis*. 1982;50:425–35.
4. World Health Organization. WHO model prescribing information: drugs used in leprosy [cited 2019 Jan 20]. <https://apps.who.int/medicinedocs/en/d/Jh2988e>
5. Gimovsky AC, Macri CJ. Leprosy in pregnant woman, United States. *Emerg Infect Dis*. 2013;19:1693–4. <http://dx.doi.org/10.3201/eid1910.130463>
6. Shale MJ. Women with leprosy. A woman with leprosy is in double jeopardy. *Lepr Rev*. 2000;71:5–17. <http://dx.doi.org/10.5935/0305-7518.20000003>
7. Ozturk Z, Tatliparmak A. Leprosy treatment during pregnancy and breastfeeding: a case report and brief review of literature. *Dermatol Ther (Heidelb)*. 2017;30:e12414. <http://dx.doi.org/10.1111/dth.12414>
8. Listed N. The final push strategy to eliminate leprosy as a public health problem: questions and answers. *Lepr Rev*. 2002;73:279–81.

Address for correspondence: Hongsheng Wang, Institute of Dermatology, Chinese Academy of Medical Sciences, Department of Mycobacterium, St. 12 Jiangwangmiao, Nanjing, Jiangsu 210042, China; email: whs33@vip.sina.com; Junhua Li, Hunan Provincial Center for Disease Control and Prevention, Changsha, Hunan, China; email: hncdcbgs@126.com

Zoonotic Virus Seroprevalence among Bank Voles, Poland, 2002–2010

Maciej Grzybek, Tarja Sironen, Sanna Mäki, Katarzyna Tołkacz, Mohammed Alsarraf, Aneta Strachecka, Jerzy Paleolog, Beata Biernat, Klaudiusz Szczepaniak, Jolanta Behnke-Borowczyk, Antti Vaheri, Heikki Henttonen, Jerzy M. Behnke,¹ Anna Bajer¹

Author affiliations: Medical University of Gdansk, Gdansk, Poland (M. Grzybek, B. Biernat); University of Helsinki, Helsinki, Finland (T. Sironen, S. Mäki, A. Vaheri); University of Warsaw, Warsaw, Poland (K. Tołkacz, M. Alsarraf, A. Bajer); University of Life Sciences in Lublin, Lublin, Poland (A. Strachecka, J. Paleolog, K. Szczepaniak); Poznan University of Life Sciences, Poznan, Poland (J. Behnke-Borowczyk); Natural Resources Institute Finland, Helsinki (H. Henttonen); University of Nottingham, Nottingham, UK (J.M. Behnke)

DOI: <https://doi.org/10.3201/eid2508.190217>

¹These authors contributed equally to this article.

Bank voles in Poland are reservoirs of zoonotic viruses. To determine seroprevalence of hantavirus, arenavirus, and cowpox virus and factors affecting seroprevalence, we screened for antibodies against these viruses over 9 years. Cowpox virus was most prevalent and affected by extrinsic and intrinsic factors. Long-term and multisite surveillance is crucial.

The most prevalent rodentborne zoonotic viruses in Europe are hantaviruses, lymphocytic choriomeningitis virus (LCMV), cowpox virus (CPXV), and Puumala virus (PUUV) (1). In 2016, a total of 18 countries in Europe reported 2,190 cases of hantavirus disease, mainly caused by PUUV. The occurrence of rodentborne viruses in Poland is not well documented. The first outbreak of hantavirus infections among humans (9 cases) was reported in 2007. During 2012–2016, a total of 79 cases of hantavirus infections were reported in Poland, 55 of them in Podkarpackie Province in 2014 (2). In 2015, a case of human cowpox infection was reported in Poland (3).

We conducted a multisite, long-term study of hantavirus and arenavirus seroprevalence in northeastern Poland. Our objectives were to monitor seroprevalence of LCMV, CPXV, and PUUV in 3 populations of bank voles (*Myodes glareolus*) from ecologically similar but disparate sites in northeastern Poland and to analyze intrinsic (host sex, host age) and extrinsic (study year, study sites) factors that might affect seroprevalence among these rodent populations.

Study sites were located in the Mazury Lake District region in northeastern Poland (Appendix Figure 1, <https://wwwnc.cdc.gov/EID/article/25/8/19-0217-App1.pdf>). The sites and methods used for trapping rodents and sampling and processing trapped animals have been described (4). We analyzed serum samples by using an immunofluorescence assay (IFA) (Appendix Figure 2). We diluted serum samples 1:10 in phosphate-buffered saline and tested their reactivity to hantaviruses by using a PUUV IFA, to cowpox viruses by using a CPXV IFA, and to arenaviruses by using an LCMV IFA (5). IFAs were conducted as previously described (6,7). The statistical approach has been comprehensively documented (4).

We tested 652 bank voles and detected antibodies against all 3 viruses. Overall seroprevalence of combined viral infections was 25.9% (95% CI 23.0%–29.1%), but most infections were attributable to CPXV (seroprevalence 25% [95% CI 22.1%–28.2%]). Only 2 voles were LCMV seropositive (0.3% [95% CI 0.2%–0.9%]), and only 5 were PUUV seropositive (0.76% [95% CI 0.4%–1.6%]). We therefore confined further analyses to CPXV.

The effect of study year on CPXV seroprevalence (by χ^2 /d.f.) was highly significant (χ^2_2 31.2; $p < 0.001$); seroprevalence was 2.7 times higher among bank voles sampled in